



# Prosthetic replacement vs space closure for maxillary lateral incisor agenesis: A systematic review

Giordani Santos Silveira,<sup>a</sup> Natália Valli de Almeida,<sup>a</sup> Daniele Masterson Tavares Pereira,<sup>b</sup> Cláudia Trindade Mattos,<sup>c</sup> and José Nelson Mucha<sup>d</sup>

Niterói, Rio de Janeiro, Brazil

**Introduction:** Defining the best treatment for maxillary lateral incisor agenesis is a challenge. Our aim in this study was to determine, with the evidence available in the literature, the best treatment for maxillary lateral incisor agenesis in the permanent dentition, evaluating the esthetic, occlusal (functional), and periodontal results between prosthetic replacement and orthodontic space closure. **Methods:** Electronic databases (CENTRAL, PubMed, Web of Science, Scopus, and LILACS) were searched in September 2014 and updated in January 2015, with no restriction on language or initial date. A manual search of the reference lists of the potential studies was performed. Risk of bias was assessed by the Newcastle Ottawa Scale. **Results:** The search identified 2174 articles, of which 1196 were excluded because they were duplicates. Titles and abstracts of 978 articles were accessed, and 957 were excluded. In total, 21 articles were read in full, and 9 case-control studies were included after applying the inclusion and exclusion criteria. Data were extracted from the articles selected, and a table was compiled for comparison and analysis of the results. There were no randomization and blinding, and the risk of bias evaluation found gaps in compatibility and outcome domains in almost all selected studies. **Conclusions:** Tooth-supported dental prostheses of maxillary lateral incisor agenesis had worse scores in the periodontal indexes than did orthodontic space closure. Space closure is evaluated better esthetically than prosthetic replacements, and the presence or absence of a Class I relationship of the canines showed no relationship with occlusal function or with signs and symptoms of temporomandibular disorders. (Am J Orthod Dentofacial Orthop 2016;150:228-37)

The ideal orthodontic treatment for maxillary lateral incisor agenesis remains a controversial topic in both academic and clinical fields, even after more than 5 decades of debate.<sup>1-3</sup> The central point of this lack of consensus is the decision between opening space for prosthetic replacement of the absent teeth or orthodontically closing the spaces, followed by anatomic recontouring of the canines.

Some authors have considered that certain clinical characteristics must be analyzed before deciding upon the best therapeutic alternative, such the patient's age, type of sagittal malocclusion, presence or absence of crowding in both dental arches, and type of facial profile.<sup>4-8</sup>

Those who defend prosthetic replacement of the absent incisors believe that canine guidance is ideal for a long-term, healthy occlusion.<sup>9,10</sup> These authors have also reported the difficulty in obtaining adequate esthetics when the canine substitutes for the lateral incisor because of the differences in color, shape, or root volume.<sup>11,12</sup> Conversely, those who defend orthodontic space closure argue that the periodontal conditions are better than those that are observed in patients with a fixed or removable prosthesis.<sup>4,13,14</sup> Furthermore, the esthetic outcome with space closure is more natural if the orthodontist performs the correct enameloplasty in the canine and adequately controls the lingual root torque.<sup>2,4,15,16</sup>

There are numerous articles on this subject, but most are narrative reviews, articles of opinion, case series, and

<sup>a</sup>Postgraduate student, Department of Orthodontics, Universidade Federal Fluminense, Niterói, Rio de Janeiro, Brazil.

<sup>b</sup>Librarian and postgraduate student, Health Science Center Library of the Universidade Federal do Rio de Janeiro, Rio de Janeiro, Brazil.

<sup>c</sup>Adjunct professor, Department of Orthodontics, Universidade Federal Fluminense, Niterói, Rio de Janeiro, Brazil.

<sup>d</sup>Professor and chair, Department of Orthodontics, Universidade Federal Fluminense, Niterói, Rio de Janeiro, Brazil.

All authors have completed and submitted the ICMJE Form for Disclosure of Potential Conflicts of Interest, and none were reported.

Address correspondence to: Giordani Santos Silveira, Rua Mário Santos Braga, 30, 2nd floor, room 214, Campus do Valonguinho—Centro-Niterói, Rio de Janeiro, Brazil, CEP 24.040-110; e-mail, [giordanisilveira@hotmail.com](mailto:giordanisilveira@hotmail.com).

Submitted, March 2015; revised and accepted, January 2016.

0889-5406/\$36.00

© 2016 by the American Association of Orthodontists. All rights reserved.

<http://dx.doi.org/10.1016/j.ajodo.2016.01.018>

case reports.<sup>1,2,5-8,17</sup> The respective 1975 and 1976 comparative studies of Nordquist and McNeill<sup>13</sup> and Senty<sup>18</sup> may be considered classics because of their pioneering nature, although in one,<sup>18</sup> the analysis was eminently subjective. In 2000, Robertsson and Mohlin,<sup>14</sup> taking advantage of the technical improvements in dental prostheses (porcelain bonded to gold and resin-bonded bridge), conducted a study that also occupies an important place in the dental literature. However, none of these 3 studies evaluated implant-supported crowns that are currently considered the ideal prosthetic option for absent teeth,<sup>12,19</sup> despite the probable esthetic problems of gingival retraction, interdental black triangles, and infraocclusion.<sup>20-24</sup>

Andrade et al<sup>25</sup> conducted a systematic review in 2011 (published in 2013) and found no scientific evidence to support any treatment option for maxillary lateral incisor agenesis because they did not identify any randomized clinical trial (RCT) or quasi-RCT. Nevertheless, these authors recognized the high complexity of this clinical problem because of the different variables involved and suggested that the best treatment might never be found if only the evidence from RCTs were considered. In accordance with the study of Papageorgiou et al,<sup>26</sup> when RCTs are not feasible or inappropriate, the clinical decision should be made on sound reasoning and scientific evidence over well-conducted prospective non-RCTs that can provide complementary evidence.

Therefore, the aim of this systematic review was to determine with the evidence available the best treatment alternative for patients with maxillary lateral incisor agenesis by comparing orthodontic space closure and implant-supported and tooth-supported dental prostheses by assessing studies that evaluated their esthetic, occlusal (functional), and periodontal results.

## MATERIAL AND METHODS

This systematic review was carried out according to the guidelines of the Preferred Reporting Items for Systematic Reviews and Meta-Analyses (PRISMA statement)<sup>27</sup> and the *Cochrane Handbook for Systematic Reviews of Interventions* (version 5.1.0).<sup>28</sup> No protocol registration was performed.

### Eligibility criteria

All studies that evaluated and compared the results—occlusal (functional), periodontal, or esthetic aspects—of the different prosthetic treatments with orthodontic space closure for patients with maxillary lateral incisor agenesis, unilateral or bilateral, in the permanent dentition were included. For prosthetic replacements, no distinction was made between those who had a previous

orthodontic intervention or not. In the space closure modality, only patients treated with fixed orthodontic appliances were included.

Other exclusion criteria were as follows: tooth loss from trauma or caries (because these could cause bone loss and confound the periodontal results), absence of other teeth in the maxilla, other dental anomalies (supernumerary, impacted, or ectopic teeth), interceptive or provisional treatments, patients with syndromes or cleft lip and palate, orthognathic surgery, review articles, opinion articles, case reports, descriptions of techniques, subjective evaluations of results without statistical analysis, studies of esthetic perception with images that were manipulated on computers, and studies that did not have a direct comparison of the treatment modalities.

### Information sources, search strategy, and study selection

The following electronic databases were searched in September 2014 without restrictions on language or initial date: Cochrane Central Register of Controlled Trials, MEDLINE via PubMed, Web of Science, Scopus, and LILACS. The search strategies were obtained under the guidance of an experienced librarian using a process of identification of key words, expressions, and their possible combinations to encompass the most studies related to our objectives. Table 1 illustrates the search strategy used in PubMed (see also the Supplemental Table). A manual search of the reference lists of the potential studies and an additional electronic search to update the results were performed in January 2015.

Duplicate articles were eliminated. The titles and abstracts were read independently by 2 reviewers (G.S.S. and N.V.A.), and the articles that had characteristics compatible with those of the inclusion criteria were selected so that the full texts were examined to confirm their eligibility.

### Data items and collection

From the articles included, the data were organized in tables, and this was also done independently by the some 2 reviewers. Ages of the participants and follow-ups were given in decimal years. Disagreements between the 2 reviewers in these 2 stages were resolved in a consensus meeting with a third researcher (C.T.M.). When a lack of data was observed in an article, an attempt was made to obtain the information by contacting the authors by e-mail.

### Risk of bias in individual studies

To assess the risk of bias of the retrospective studies selected, an adaptation of the Newcastle-Ottawa Scale

**Table I.** Parameters used for the search in 1 database

Database	Search strategies
Pubmed	("upper lateral incisor"[tiab] OR "maxillary lateral incisor"[tiab] OR incisor[MH] OR incisor[tiab]) AND (anodontia[mh] OR anodontia[tiab] OR "teeth agenesis"[tiab] OR "tooth agenesis"[tiab] OR hypodontia[tiab] OR oligodontia [tiab] OR "dental agenesis"[tiab] OR "partial anodontia"[tiab] OR "missing teeth"[tiab] OR "missing tooth"[tiab] OR "absent teeth"[tiab] OR "absent tooth"[tiab] OR "congenitally missing"[tiab] OR "congenitally absent"[tiab] OR missing[tiab] OR absent[tiab]) AND (Orthodontics[MH] OR "orthodontic treatment"[tiab] OR "orthodontic therapy"[tiab] OR Tooth movement[MH] OR "orthodontic movement"[tiab] OR "teeth movement"[tiab] OR Orthodontic space closure[MH] OR "orthodontic space closure"[tiab] OR "orthodontic dental space closure"[tiab] OR "canine substitution"[tiab] OR "mesial movement of canine"[tiab] OR "mesial movement of cuspid"[tiab] OR Dental implants[MH] OR "dental implant"[tiab] OR "single tooth implant"[tiab] OR "single-tooth implant"[tiab] OR "single-tooth implants"[tiab] OR "single-tooth dental implant"[tiab] OR Denture, partial, fixed[MH] OR "Denture partial fixed"[tiab] OR fixed bridge* OR "fixed partial denture"[tiab] OR pontic[tiab] OR Denture, partial, removable[MH] OR "denture removable partial"[tiab] OR Denture, partial, fixed, resin-bonded[mh] OR "maryland bridge dental"[tiab] OR "resin-bonded bridge"[tiab] OR "resin-bonded fixed partial denture"[tiab] OR "resin- bonded acid etched fixed partial denture"[tiab] OR Dental prosthesis[MH] OR "dental prosthesis"[tiab] OR "prosthetic replacement"[tiab] OR Dental prosthesis, implant-supported[MH] OR "prosthesis implant-supported dental"[tiab])

was used with 9 specific domains.<sup>29</sup> This was a "star" system in which a star is marked in each domain if this is identified as satisfactory in the study. Two reviewers (G.S.S. and N.V.A.) independently evaluated the risk of each study, and disagreements were resolved in a meeting with a third researcher (C.T.M.).

### Summary measures and approach to synthesis

As a result of the heterogeneity among the studies included in this systematic review, particularly in their designs and the variables evaluated, it was not feasible to perform a meta-analysis. A qualitative synthesis was performed by comparing the results from individual studies according to the groups evaluated (with statistical significance). The incorporation of the risk of bias into the qualitative synthesis was not possible because of the heterogeneity among the studies and the characteristics described.

## RESULTS

### Study selection and characteristics

The initial search identified 2174 articles, but 1196 were excluded because they were duplicates. The titles and abstracts of the 978 remaining articles were accessed, and 957 were excluded because they were not related to the subject or did not fulfill the eligibility criteria. Twenty-one articles were read in full, and 12 were excluded for the following reasons: absence of teeth in the maxilla other than lateral incisors,<sup>24,30-36</sup> orthodontic treatment with removable appliances,<sup>37,38</sup> or comparison of the esthetic demands of different social groups without distinction between the types of treatment,<sup>39</sup> and occlusal and esthetic descriptive evaluations with a highly subjective nature and without

quantitative criteria.<sup>18</sup> The 9 articles that met the inclusion criteria were case-control studies that compared the results of different types of treatment and were included in this review (Fig).<sup>13,14,40-46</sup>

[F1-4/C]

Three studies compared the periodontal and occlusal results in patients with space closure with tooth-supported<sup>13,14</sup> and implant-supported dental prostheses.<sup>41</sup> One study<sup>14</sup> also compared the esthetic results, evaluated by the patients themselves, and 2 studies evaluated signs and symptoms of temporomandibular disorders (TMDs).<sup>14,41</sup>

The other 6 studies compared only the esthetic results of the different types of treatment.<sup>40,42-46</sup> In 3 studies, dental professionals and laypersons evaluated photographs without knowing the type of treatment performed.<sup>40,42,43</sup> In the other 3 studies, different esthetic criteria were used, such as width-to-height ratio, gingival zenith of the maxillary lateral incisor, golden proportion in the 6 anterior teeth, and apparent contact dimension in the same sample, varying only between subjects with unilateral or bilateral agenesis.<sup>44-46</sup> This information was obtained from an author by e-mail contact, and data not reported in the articles were obtained: ages of the subjects and time of posttreatment evaluation (Table II). This same research group also conducted the study that compared the functional and periodontal aspects for both space closure and implant-supported dental prostheses.<sup>41</sup>

### Risk of bias assessment in studies

The result of the risk of bias assessment with an adaptation of the Newcastle-Ottawa Scale to case-control studies showed gaps in compatibility (study controls for other factors than age) and outcome (follow-up durations) domains (Table III) in almost all studies. In addition

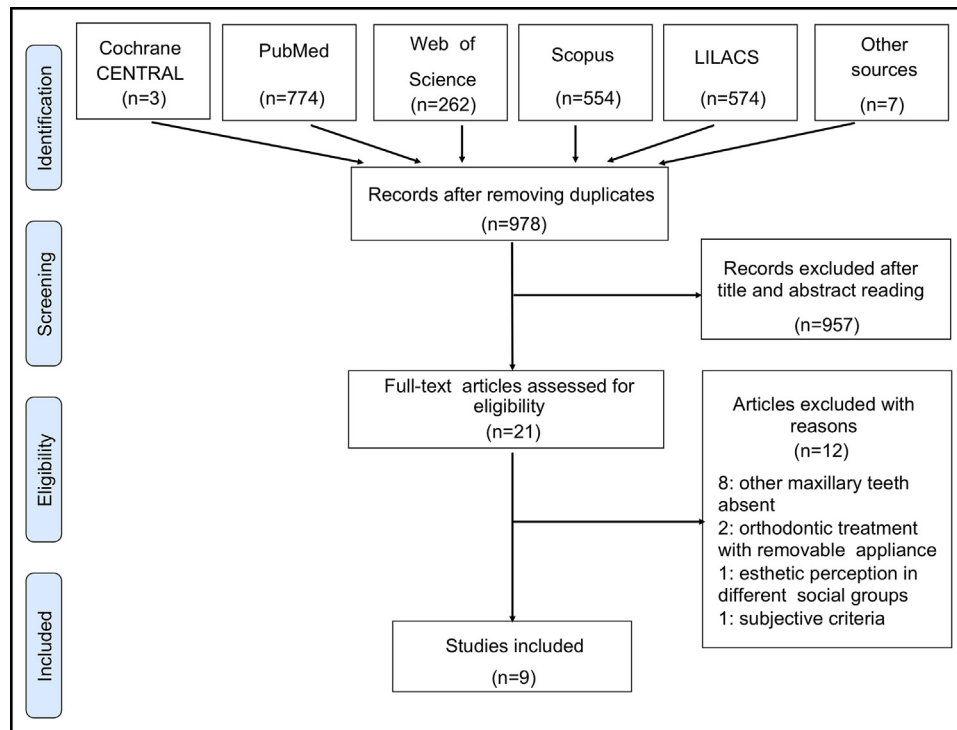


Fig. PRISMA flowchart of study selection.

to sample size calculation, random sequence generation, blinding of allocation, and blinding of measures had not been done and could have contributed to biases.

**Periodontal status**

The periodontal evaluation compared treatments with the indexes that categorize edema and gingival color, bleeding on probing, ulcerations, retentive factors, quantity of bacterial plaque, probing depth, gingival retraction on the vestibular surface, and filling of the interdental space by the papilla (Table II).<sup>13,14,41</sup> No study confirmed that porcelain bonded to gold and resin-bonded bridges could obtain better periodontal results than orthodontic space closure.<sup>14</sup> With regard to the prevalence of gingival dehiscence on the vestibular surface of maxillary premolars, no study found a significant difference between the groups.<sup>13,14,41</sup> When space closure was compared with implant-supported dental prostheses, there was less filling of the interdental space by the papilla between the central and lateral incisors in the implant group.<sup>41</sup>

**Occlusal function**

The occlusion<sup>13,14</sup> and the signs and symptoms of TMDs<sup>14,41</sup> were compared according to the types of

treatment. The occlusal evaluation was measured by a canine rise or a group function, the number of contacts on the working side, the difference between centric relation and centric occlusion in the anterior and lateral direction, the number of premature contacts on the side of balance, and the number of premature contacts on the anterior guide. Signs of TMDs were obtained in clinical examinations, and symptoms were determined in questionnaires, based on the Helkimo index.<sup>14,41</sup>

Two studies found statistically significant differences only in the prevalence of group function, which was present in 100%<sup>13</sup> and 96%<sup>14</sup> of the space closure groups and in 89%<sup>13</sup> and 67%<sup>14</sup> of the prosthetic replacement groups. For De Marchi et al,<sup>41</sup> 42% of the space closure group and 20% of the group with implants had a group function with no difference in the prevalence of abfraction. No statistically significant differences were found in the TMD index (modified Helkimo) between the space closure and the prosthetic replacement groups (Table II).<sup>14,41</sup>

**Esthetics**

Robertsson and Mohlin<sup>14</sup> used a questionnaire, in which the opinions of the patients were assessed with regard to the shape, color, and symmetry of the teeth and

**Table II.** Data extracted from studies in this systematic review

Study	Design	Participants (sex): treatment modalities	LI agenesis (bilateral or unilateral)	Patients age (y): mean (range)	Objective	Parameters evaluated	Method of measurement	Statistical analysis (level of significance)	Results	Follow-up: mean (range)
Nordquist and McNeill, <sup>13</sup> 1975	Case control	33 patients (not reported): not reported	25 patients (bilateral) 8 patients (unilateral)	Not reported	To compare OSC, FPD, and RPD	Occlusal function Periodontal status	Clinical examination	F ratio, <i>t</i> test ANOVA for 1-way design ( <i>P</i> = 0.01)	Periodontal status (OSC>RPD=FPD) Occlusal function (OSC=FPD=RPD)	9.7 y (2.3-25.5 y)
Robertsson and Mohlin, <sup>14</sup> 2000	Case control	50 patients (M, 14; F, 36): 30 OSC, 20 FPD	39 patients (bilateral) 11 patients (unilateral)	25.8 y (18.4-54.9 y)	To compare OSC and FPD	Occlusal function Signs and symptoms of TMDs Periodontal status Esthetics	Clinical examination and questionnaire	<i>t</i> test chi-square ( <i>P</i> = 0.05)	Occlusal function (OSC=FPD) Esthetic (OSC>FPD) Periodontal status (OSC>FPD)	7.1 y (0.5-13.9 y)
Armbruster et al, <sup>42</sup> 2005	Case control	12 subjects (not reported): 3 MB, 3 DI, 3 OSC, 3 ND Evaluators: 43 orthodontists, 140 general dentists, 29 specialists, 40 laypersons	6 patients (bilateral) 3 patients (unilateral)	Not reported	To compare OSC, DI, MB, and ND	Esthetics	Intrabuccal photos	2-way ANOVA 1-way ANOVA Student Newman-Keuls ( <i>P</i> = 0.05)	Laypersons (OSC>ND>MB>DI) General dentists (ND>OSC>MB>DI)	Not reported
Thams et al, <sup>43</sup> 2009	Case control	12 subjects (not reported): 2 MB, 3 DI, 4 OSC, 3 NT Evaluators: 15 orthodontists, 15 general dentists, 15 laypersons	Not reported (bilateral and unilateral)	Not reported	To compare OSC, DI, MB, and NT	Esthetics	Intrabuccal photos	ANOVA ( <i>P</i> = 0.05)	All groups of evaluators (OSC>DI>MB>NT)	Not reported
De Marchi et al, <sup>41</sup> 2012	Case control	68 subjects (M, 52; F, 16): 26 OSC, 20 DI, 22 ND	27 patients (bilateral) 19 patients (unilateral)	OSC: 24.9 y (14.1-41.1) DI: 25.1 y (19.0-45.1) ND: 21.3 y (19.1-26.1)	To compare OSC, DI, and ND	Periodontal status Signs and symptoms of TMDs	Clinical examination and questionnaire	Fisher exact test Shapiro-Wilk Mann-Whitney test Nonparametric Kruskal-Wallis ( <i>P</i> = 0.05)	Periodontal status: plaque index, bleeding on probing, probing depth, gingival recession (OSC=DI=CG) PIS (OSC=CG>DI) Signs and symptoms of TMDs (OSC=DI=CG)	OSC: 3.9 y DI: 3.5 y
Pini et al, <sup>44</sup> 2012	Case control	52 subjects (not reported): 18 OSC, 10 DI, 24 ND	28 patients (bilateral)	OSC: 32.4 y DI: 32.7 y ND: 21.3 y	To compare OSC, DI, and ND	Esthetics	Dental cast	Shapiro-Wilk Wilcoxon Kruskal-Wallis <i>t</i> test ANOVA ( <i>P</i> = 0.05)	WHR: CI, LI, C (OSC=DI=ND) GZ: LI (OSC=DI=ND)	OSC: 5 y DI: 3 y

Table II. Continued

Study	Design	Participants (sex): treatment modalities	LI agenesis (bilateral or unilateral)	Patients age (y): mean (range)	Objective	Parameters evaluated	Method of measurement	Statistical analysis (level of significance)	Results	Follow-up: mean (range)
Pini et al, <sup>45</sup> 2012	Case control	48 patients (M, 9; F, 39): 28 OSC, 20 DI 25 subjects: ND	28 patients (bilateral) 20 patients (unilateral)	OSC: 24.9 y (14.1-41.1) DI: 25.1 y (19.0-45.1) ND: 21.3 y (19.1-26.1)	To compare OSC, DI, and ND	Esthetics	Dental cast	Shapiro-Wilk Wilcoxon Kruskal-Wallis Mann-Whitney U post hoc Friedman Post hoc Wilcoxon ( <i>P</i> = 0.05)	GP Yes CI:LI (DI=ND>OSC) No LI:C (DI=ND=OSC) WHR: LI (mean) (DI=ND<OSC)	OSC: 4.7 y DI: 2.7 y
Pini et al, <sup>46</sup> 2013	Case control	52 subjects (not reported): 18 OSC, 10 DI, 24 ND	28 patients (bilateral)	OSC: 32.4 DI: 32.7 y ND: 21.3 y	To compare OSC,DI, and ND	Esthetics	3D digital image from dental cast	Shapiro-Wilk Spearman correlation Kruskal-Wallis ( <i>P</i> = 0.05)	WHR: CI, LI, C (OSC=DI=ND) GZ: LI (OSC<ND=DI) ACD: (DI>OSC=ND)	OSC: 5 y DI: 3 y
De-Marchi et al, <sup>40</sup> 2014	Case control	68 subjects (M, 52; F, 16): 26 OSC, 20 DI, 22 ND Evaluators: 20 dentists, 20 laypersons, 68 patients (self- evaluation)	27 patients (bilateral) 19 patients (unilateral)	OSC: 24.9 y (14.1-41.1) DI: 25.1 y (19.0-45.1) ND: 21.3 y (19.1-26.1)	To compare OSC, DI, and ND	Esthetics	Photo of smile– lower third of the face (visual analog scales)	Fischer post hoc Mann-Whitney Shapiro-Wilk <i>t</i> test Cronbach $\alpha$ ICC Kolmogorov- Smirnov Multifactorial ANOVA 1-way ANOVA Bonferroni correction ( <i>P</i> = 0.05)	Laypersons and dentists (OSC=DI=ND) Self-evaluation (OSC=DI>ND) (OSC=DI) (OSC>ND) (DI=ND)	OSC: 3.9 y DI: 3.5 y

LI, Maxillary lateral incisor; OSC, orthodontic space closure; FPD, fixed partial denture; RPD, removable partial denture; ANOVA, analysis of variance; M, Male; F, female; TMDs, temporomandibular disorders; DI, dental implant; MB, Maryland bridge; ND, normal dentition; NT, lateral incisor agenesis not treated; >, more favorable or more (with statistical difference); =, similar (without statistical difference); <, less favorable or less (with statistical difference); CG, control group; PI, plaque index; PIS, papilla index score; CI, maxillary central incisor; C, maxillary canine; GP, golden proportion; WHR, width/height ratio; GZ, gingival zenith; ACD, apparent contact dimension.

Table III. Assessment of quality of observational studies (retrospective)

Study	Selection					Compatibility		Outcome		
	Design	Case definition	Representative of the cases	Selection of controls	Definition of controls	Study controls for age	Study controls for any additional factor	Assessment of outcome	Method of ascertainment	Follow-up duration
Nordquist and McNeill, <sup>13</sup> 1975	Case control	★	★	★	★			★	★	
Robertsson and Mohlin, <sup>14</sup> 2000	Case control	★	★	★	★	★	★	★	★	
Arnbruster et al, <sup>42</sup> 2005	Case control	★			★			★	★	
Thams et al, <sup>43</sup> 2009	Case control	★			★			★	★	
De Marchi et al, <sup>41</sup> 2012	Case control	★	★	★	★	★		★	★	
Pini et al, <sup>44</sup> 2012	Case control	★	★	★	★	★		★	★	
Pini et al, <sup>45</sup> 2012	Case control	★	★	★	★	★		★	★	
Pini et al, <sup>46</sup> 2013	Case control	★	★	★	★	★		★	★	
De-Marchi et al, <sup>40</sup> 2014	Case control	★	★	★	★	★		★	★	

the distribution of spaces between them in the anterior region of the maxilla. The results showed no significant differences between the groups, except for the color of teeth close to the central incisors; 80% of the patients in the prosthetic replacement group were satisfied compared with 45% in the space closure group ( $P < 0.01$ ). De Marchi et al<sup>40</sup> used a visual analog scale regarding satisfaction with smile esthetics; when considered alone, the space closure group was evaluated as the best.

Pini et al<sup>44,46</sup> analyzed the width-to-height ratio of the 6 anterior teeth and the gingival zenith of the tooth or the dental prosthesis located in the position of the lateral incisor. There were no differences between the 3 groups (orthodontic space closure, dental implants, and normal dentition) in the 2 parameters.<sup>44</sup> The apparent contact dimension, obtained by measuring the distance from the gingival papilla crest to the point of contact, showed greater exposure of the interdental space ( $P < 0.05$ ) in the implant group than in the orthodontic space closure and normal dentition groups.<sup>46</sup>

## DISCUSSION

During the bibliographic searches to conduct this study, 2 systematic reviews were identified.<sup>20,25</sup> One selected the articles that compared space closure with implants in patients without any maxillary anterior teeth.<sup>20</sup> The authors of the other review<sup>25</sup> contemplated only the treatment of maxillary lateral incisor agenesis and, in spite of not finding any RCTs, presented 3 studies.<sup>14,31,37</sup> Considering the articles included in both reviews, only 1 article<sup>14</sup> fulfilled the inclusion criteria and was selected for our review, because the others studies either evaluated treatments with agenesis of other teeth<sup>22,23,32,35</sup> or considered only removable orthodontic appliances.<sup>37</sup>

When analyzing the studies selected for this review, we observed that the data extracted continued to be obtained from retrospective studies. Because of the lack of comparative prospective studies, there are possible pitfalls in trying to compare treatments indirectly with retrospective studies.

The indications for both opening and maintaining space and for closure with movement of the canines in the mesial direction were supported mainly by the patients' oral characteristics. A 35-year-old Class III patient with anterior deficiency of the upper lip does not have the same indication for treatment as a 15-year-old Class II patient with dental and upper lip protrusion and aligned mandibular arch.<sup>20</sup> Therefore, generation of a random sequence in the distribution of the sample between these 2 treatment groups is an ethics barrier when a prospective comparative study is being

conducted. One possibility, despite its difficulty, is to identify patients for whom both space closure and implant placement could be indicated and then randomize them.

Blinding of outcome measurements becomes unfeasible because the treatment modality is identifiable in the clinical examination. There is no way to guarantee that the examiner performs the measurements and completely excludes his or her bias. Within the parameters evaluated in the selected studies, the esthetic evaluation demonstrated the possibility of blinding the measurements when a layperson was the evaluator. Using dentists as evaluators may be questionable in this domain because in some photographs it is possible to identify the type of treatment performed.

Patients with tooth-supported dental prostheses, irrespective of the modality, have worse periodontal conditions than do those with space closure, in which there are only natural teeth.<sup>13,14</sup> Factors leading to bacterial plaque retention, such as pontics, clasps on removable dentures and eventual excessive contours, and maladaptations to teeth abutting conventional fixed dentures, have been pointed to as the main features responsible for this condition. No studies<sup>13,14,41</sup> that evaluated space closure made reference to fixed splinting, in spite of the recognized tendency toward reopening spaces and the recommendation to bond them for stable results.<sup>4,15,16,47</sup>

On the other hand, implant-supported dental prostheses showed a tendency toward plaque retention similar to that in patients with space closure.<sup>41</sup> Three important periodontal problems are related to implants in the anterior region of the maxilla, with consequent unfavorable esthetic effects: vestibular gingival retraction,<sup>20-23,30</sup> incomplete filling of the interdental space by the papilla,<sup>48</sup> and infraocclusion of the implant,<sup>20-23,33</sup> especially in 10-year follow-ups. Furthermore, there are reports of bone loss around the implants, with high variability among subjects.<sup>22,23</sup>

Comparison of the gingival papillae between the patients with space closure and those with implants showed less filling of the interdental spaces between the central and lateral incisors in the implant group.<sup>41,46</sup> Also, the patients evaluated in these articles were young adults, and these variables have a tendency to worsen over the years.<sup>20,30,41</sup> The papillae shape can be influenced by orthodontic movement and the distance between implant and adjacent teeth.<sup>7</sup> One must also expect a loss of leveling between the implant crown and the adjacent teeth over time because of the continual eruption of natural teeth,<sup>20-22</sup> even in adult patients.<sup>33</sup> This situation becomes more critical from an esthetic point of view: eg, in patients with a gummy smile and unilateral replacement.<sup>20,22,23</sup>

Comparison of the results of Nordquist and McNeill<sup>13</sup> and other studies<sup>14,41</sup> during a time when significant technical improvements in prosthetic replacements and scientific methodologies were made limits definitive conclusions.

The width-to-height comparison in the 6 anterior teeth showed a greater width of canines moved in the mesial direction and a greater height of implants than that of natural lateral incisors.<sup>44</sup> The adequate position of the lateral incisor's gingival zenith in space closure patients was apparently critical to obtain. The prevalence of the golden proportion was low in maxillary lateral incisor agenesis, irrespective of the treatment modality, and similar to that of other studies that investigated it in healthy dentitions.<sup>45</sup>

Beyond these technical aspects, it is fundamental to know the esthetic perceptions of laypersons and patients concerning the results of each treatment modality. In 3 studies that evaluated esthetic perceptions, the laypersons and patients believed that the results with space closure had a better esthetic appearance than those of tooth-supported or implant-supported dental prostheses.<sup>14,42,43</sup>

Adhesive Maryland bridges alternated with implants in the ranking as having the worst esthetic appearance in the opinions of laypersons and dentists.<sup>42,43</sup> Curiously, when the cases with the best esthetic results were evaluated, the modality with the worst scores was replacement with implant,<sup>42</sup> whereas in cases of median results "what one sees in the streets and not those that are shown at congresses"<sup>43</sup> showed that the adhesive Maryland bridge prostheses were considered the worst. However, there are limitations to this type of study design when there is a standard for neither age of the patients nor posttreatment time of the results that are being evaluated.<sup>43</sup>

Canine guidance in most studies was infrequent. Surprisingly, in patients with prosthetic replacements, only 11%<sup>13</sup> and 33%<sup>14</sup> of the quadrants had a canine rise, whereas in another study, a canine rise was found in 80% of the group with canines in a Class I relationship.<sup>41</sup> In a first analysis, one could infer that the orthodontists in the latter study<sup>41</sup> were more diligent in that they obtained a canine-protected occlusion more frequently than the orthodontists in the other 2 studies.<sup>13,14</sup> However, in the former 2 studies, the mean follow-up times were 7 years<sup>14</sup> and 10 years,<sup>13</sup> whereas in the latter study it was 3 years.<sup>41</sup> A canine-protected occlusion may not be considered completely stable because with the passage of years it tends to be replaced by group function because of the inevitable and common wear of the maxillary canines.<sup>49,50</sup> Moreover, this is not necessarily a cause of TMDs.<sup>14,41,49,51</sup> The etiology of



TMDs is multifactorial, and static and functional occlusions play a secondary role,<sup>49-53</sup> ranging from 10% to 20%, without, however, being directly related in the context of cause and effect.<sup>51</sup>

The prosthetic replacement did not prove to be better than orthodontic space closure, considering the findings of the studies, which evaluated the results of the different options for the treatment of maxillary lateral incisor agenesis. It could be suggested that orthodontic space closure would be the option of choice if the diagnosis characteristics allow it.

### Limitations

These findings must be interpreted and evaluated in conjunction with the expectations of the patients and those responsible for them, the experience and interdisciplinary composition of the professional team, and the financial constraints to achieve the best possible treatment for each patient, while respecting his or her particularities.

Prospective controlled studies are necessary to provide more compelling scientific evidence; however, because of the difficulties and limitations imposed on the investigation of this subject, perhaps the next achievements will be evidenced in the results of new retrospective studies that try to eliminate some of the gaps in the previous studies, as pointed out in this review: eg, incompatibility between compared groups, absence of sample calculation, lack of blinding of the evaluation (when possible), and relatively short post-treatment evaluations.

This systematic review has specific limitations: the included studies were biased, and there was no searching in the gray literature.

### CONCLUSIONS

1. Tooth-supported dental prostheses for maxillary lateral incisor agenesis have worse scores in the periodontal indexes (gingival index, plaque index, papilla index, irritant index, bone loss, and probing depth) than orthodontic space closure treatment.
2. The esthetic limitations of fixed tooth-supported and implant-supported dental prostheses arouse greater criticism in laypersons, patients, and dentists than space closure treatment, which was evaluated more favorably.
3. The presence or absence of a canine rise in the treatment of lateral incisor agenesis showed no relationship to occlusal function or to the signs and symptoms of TMDs. A Class I relationship of the canines does not necessarily presuppose the presence of a canine-protected occlusion.

### ACKNOWLEDGMENTS

We thank Dauro Douglas Oliveira for suggestions and revision of the manuscript.

### SUPPLEMENTARY DATA

Supplementary data related to this article can be found at <http://dx.doi.org/10.1016/j.ajodo.2016.01.018>.

### REFERENCES

1. Carlson H. Suggested treatment for missing lateral incisor cases. *Angle Orthod* 1952;22:205-16.
2. Tuverson DL. Orthodontic treatment using canines in place of missing maxillary lateral incisors. *Am J Orthod* 1970;58:109-27.
3. Johal A, Katsaros C, Kuijpers-Jagtman AM. Angle Society of Europe membership. State of the science on controversial topics: missing maxillary lateral incisors—a report of the Angle Society of Europe 2012 meeting. *Prog Orthod* 2013;14:20.
4. Rosa M, Zachrisson BU. Integrating esthetic dentistry and space closure in patients with missing maxillary lateral incisors. *J Clin Orthod* 2001;35:221-34.
5. Kokich VO Jr, Kinzer GA. Managing congenitally missing lateral incisors. Part I: canine substitution. *J Esthet Restor Dent* 2005;17:5-10.
6. Kinzer GA, Kokich VO Jr. Managing congenitally missing lateral incisors. Part II: tooth-supported restorations. *J Esthet Restor Dent* 2005;17:76-84.
7. Kinzer GA, Kokich VO Jr. Managing congenitally missing lateral incisors. Part III: single-tooth implants. *J Esthet Restor Dent* 2005;17:202-10.
8. Araújo EA, Oliveira DD, Araújo MT. Diagnostic protocol in cases of congenitally missing maxillary lateral incisors. *World J Orthod* 2006;7:376-88.
9. D'Amico A. The canine teeth: normal functional relation of the natural teeth of man. *J S Calif Dent Assoc* 1958;26:6-23.
10. Roth RH. The maintenance system and occlusal dynamics. *Dent Clin North Am* 1976;20:761-88.
11. McNeill RW, Joondeph DR. Congenitally absent maxillary lateral incisors: treatment planning considerations. *Angle Orthod* 1973;43:24-9.
12. Kokich VO Jr, Kinzer GA, Janakievski J. Congenitally missing maxillary lateral incisors: restorative replacement [Point/Counterpoint]. *Am J Orthod Dentofacial Orthop* 2011;139:434-45.
13. Nordquist GG, McNeill RW. Orthodontic vs. restorative treatment of the congenitally absent lateral incisor—long term periodontal and occlusal evaluation. *J Periodontol* 1975;46:139-43.
14. Robertsson S, Mohlin B. The congenitally missing upper lateral incisor. A retrospective study of orthodontic space closure versus restorative treatment. *Eur J Orthod* 2000;22:697-710.
15. Rosa M, Zachrisson BU. Integrating space closure and esthetic dentistry in patients with missing maxillary lateral incisors. *J Clin Orthod* 2007;41:563-73.
16. Zachrisson BU, Rosa M, Toreskog S. Congenitally missing maxillary lateral incisors: canine substitution [Point/Counterpoint]. *Am J Orthod Dentofacial Orthop* 2011;139:434-45.
17. Oliveira DD, de Oliveira BF, da Mata Cid Pinto LS, Figueiredo DS, Pithon MM, Seraidarian PI. Interdisciplinary treatment of a class III patient with congenitally absent maxillary lateral incisors. *J Esthet Restor Dent* 2013;25:242-53.
18. Senty EL. The maxillary cuspid and missing lateral incisors: esthetics and occlusion. *Angle Orthod* 1976;46:365-71.

19. Millar BJ, Taylor NG. Lateral thinking: the management of missing upper lateral incisors. *Br Dent J* 1995;179:99-106.
20. Thilander B. Orthodontic space closure versus implant placement in subjects with missing teeth. *J Oral Rehabil* 2008;35(Suppl 1):64-71.
21. Iseri H, Solow B. Continued eruption of maxillary incisors and first molars in girls from 9 to 25 years, studied by the implant method. *Eur J Orthod* 1996;18:245-56.
22. Thilander B, Odman J, Jemt T. Single implants in the upper incisor region and their relationship to the adjacent teeth. An 8-year follow-up study. *Clin Oral Implants Res* 1999;10:346-55.
23. Thilander B, Odman J, Lekholm U. Orthodontic aspects of the use of oral implants in adolescents: a 10-year follow-up study. *Eur J Orthod* 2001;23:715-31.
24. Jemt T, Ahlberg G, Henriksson K, Bondevik O. Changes of anterior clinical crown height in patients provided with single-implant restorations after more than 15 years of follow-up. *Int J Prosthodont* 2006;19:455-61.
25. Andrade DCM, Loureiro CA, Araújo VE, Riera R, Atallah AN. Treatment for agenesis of maxillary lateral incisors: a systematic review. *Orthod Craniofac Res* 2013;16:129-36.
26. Papageorgiou SN, Xavier GM, Cobourne MT. Basic study design influences the results of orthodontic clinical investigations. *J Clin Epidemiol* 2015;68:1512-22.
27. Moher D, Liberati A, Tetzlaff J, Altman DG, Group Prisma. Preferred reporting items for systematic reviews and meta-analyses: the PRISMA statement. *Ann Intern Med* 2009;151:264-70.
28. Higgins JPT, Green S. *Cochrane handbook for systematic reviews of interventions*, version 5.1.0 (updated March 2011). Cochrane Collaboration; 2011. Available at: [www.cochrane-handbook.org](http://www.cochrane-handbook.org). Accessed January 5, 2015.
29. Wells GA, Shea B, O'Connell D, Peterson J, Welch V, Losos M, et al. The Newcastle-Ottawa Scale (NOS) for assessing the quality of non-randomised studies in meta-analyses. Available at: [http://www.ohri.ca/programs/clinical\\_epidemiology/oxford.htm](http://www.ohri.ca/programs/clinical_epidemiology/oxford.htm). Accessed August 28, 2015.
30. Thordarson A, Zachrisson BU, Mjör IA. Remodeling of canines to the shape of lateral incisors by grinding: a long-term clinical and radiographic evaluation. *Am J Orthod Dentofacial Orthop* 1991;100:123-32.
31. Dueled E, Gotfredsen K, Trab Damsgaard M, Hede B. Professional and patient-based evaluation of oral rehabilitation in patients with tooth agenesis. *Clin Oral Implants Res* 2009;20:729-36.
32. Arisan V, Bölükbaşı N, Ersanli S, Ozdemir T. Evaluation of 316 narrow diameter implants followed for 5-10 years: a clinical and radiographic retrospective study. *Clin Oral Implants Res* 2010;21:296-307.
33. Bernard JP, Schatz JP, Christou P, Belser U, Kiliaridis S. Long-term vertical changes of the anterior maxillary teeth adjacent to single implants in young and mature adults. A retrospective study. *J Clin Periodontol* 2004;31:1024-8.
34. Villani S, Stellzig A, Komposch G. Hypodontia: considerations on orthodontic therapy in agenesis of the permanent upper lateral incisor. *Minerva Stomatol* 1995;44:211-22.
35. Zeisner G, Witt E. Periodontal and esthetic aspects of orthodontic frontal space closure—results of a long-term study. *Fortschr Kieferorthop* 1991;52:257-62.
36. Kess K, Witt E. The long-term results in orthodontic closure of a gap in the anterior teeth—the functional status. *Fortschr Kieferorthop* 1991;52:93-7.
37. Holm U. Problems of the closing of spaces and compensatory extraction in agenesis of upper lateral incisors. *Fortschr Kieferorthop* 1971;32:233-47.
38. Harzer W, Reinhardt A. Limiting factors of functional adaptation to orthodontic space closure. *Eur J Orthod* 1990;12:354-7.
39. Robertsson S, Mohlin B, Thilander B. Aesthetic evaluation in subjects treated due to congenitally missing maxillary laterals. A comparison of perception in patients, parents and dentists. *Swed Dent J* 2010;34:177-86.
40. De-Marchi LM, Pini NI, Ramos AL, Pascotto RC. Smile attractiveness of patients treated for congenitally missing maxillary lateral incisors as rated by dentists, laypersons, and the patients themselves. *J Prosthet Dent* 2014;112:540-6.
41. De Marchi LM, Pini NI, Hayacibara RM, Silva RS, Pascotto RC. Congenitally missing maxillary lateral incisors: functional and periodontal aspects in patients treated with implants or space closure and tooth re-contouring. *Open Dent J* 2012;6:248-54.
42. Armbruster PC, Gardiner DM, Whitley JB Jr, Flerra J. The congenitally missing maxillary lateral incisor. Part 1: esthetic judgment of treatment options. *World J Orthod* 2005;6:369-75.
43. Thams V, Tarjuelo I, Rico M, García-Camba P, Díaz A, Vázquez S, et al. Agenesis de incisivos laterales superiores: valoración estética de las distintas opciones terapéutica. *Cient Dent* 2009;6:103-9.
44. Pini NIP, De-Marchi LM, Gribel BF, Ramos AL, Furquim LZ, Pascotto RC. Analysis of width/height ratio and gingival zenith in patients with bilateral agenesis of maxillary lateral incisor. *Dent Press J Orthod* 2012;17:87-93.
45. Pini NP, De-Marchi LM, Gribel BF, Ubal dini AL, Pascotto RC. Analysis of the golden proportion and width/height ratios of maxillary anterior dentition in patients with lateral incisor agenesis. *J Esthet Restor Dent* 2012;24:402-14.
46. Pini NP, De-Marchi LM, Gribel BF, Pascotto RC. Digital analysis of anterior dental esthetic parameters in patients with bilateral maxillary lateral incisor agenesis. *J Esthet Restor Dent* 2013;25:189-200.
47. Zachrisson BU. Long-term experience with direct-bonded retainers. Update and clinical advice. *J Clin Orthod* 2007;41:728-37.
48. Belser UC, Grütter L, Vailati F, Bornstein MM, Weber HP, Buser D. Outcome evaluation of early placed maxillary anterior single-tooth implants using objective esthetic criteria: a cross-sectional, retrospective study in 45 patients with a 2- to 4-year follow-up using pink and white esthetic scores. *J Periodontol* 2009;80:140-51.
49. Rinchuse DJ, Kandasamy S, Sciote J. A contemporary and evidence-based view of canine protected occlusion. *Am J Orthod Dentofacial Orthop* 2007;132:90-102.
50. Storey AT. Functional stability of orthodontic treatment: occlusion as a cause of temporomandibular disorders. In: Nanda R, Burstone CJ, editors. *Retention and stability in orthodontics*. Philadelphia: Saunders; 1993. p. 203-15.
51. McNamara JA Jr, Seligman DA, Okeson JP. Occlusion, orthodontic treatment, and temporomandibular disorders: a review. *J Orofac Pain* 1995;9:73-90.
52. Tipton RT, Rinchuse DJ. The relationship between static occlusion and functional occlusion in a dental school population. *Angle Orthod* 1991;61:57-66.
53. Meng HP, Dibbets JM, van der Weele LT, Boering G. Symptoms of temporomandibular joint dysfunction and predisposing factors. *J Prosthet Dent* 1987;57:215-22.