

TRAUMATIC BONE CYST – REPORT OF A CASE DIAGNOSED AFTER ORTHODONTIC TREATMENT

*CISTO ÓSSEO TRAUMÁTICO – RELATO DE CASO DIAGNOSTICADO
APÓS TRATAMENTO ORTODÔNTICO*

Motta, Andrea Fonseca Jardim da*
Torres, Sandra Regina**
Coutinho, Antonio Carlos de Azeredo***

SUMMARY

Traumatic bone cyst is an uncommon lesion that may be incidentally diagnosed in routine dental treatment. Clinical features may comprehend asymptomatic lesion, with no bone expansion, most commonly located on the posterior mandible area. The lesion affects most often patients on second decade of life. Radiographically traumatic bone cyst it is manifested as a well-defined radiolucent area with a festooned pattern around the apices of the adjacent teeth. Routine radiographies play an important role in diagnosing this lesion. In most of the cases the diagnosis is confirmed by the finding of an empty cavity during surgical management. Simple exploration of the cyst may be the curative procedure for this lesion. The present study reports a clinic case in which traumatic bone cyst had been diagnosed during final documentation at the end of the orthodontic treatment.

UNITERMS: *traumatic bone cyst; diagnosis; radiography; orthodontic treatment.*

RESUMO

O cisto ósseo traumático é uma condição incomum que pode ser diagnosticada ao acaso em tratamento odontológico de rotina. Os aspectos clínicos envolvem lesão assintomática, sem expansão óssea, mais comumente localizada na região posterior da mandíbula, afetando preferencialmente indivíduos na segunda década de vida. Radiograficamente, o cisto ósseo traumático apresenta uma área radiolúcida bem definida, com padrão festonado ao redor dos ápices dos dentes adjacentes. As radiografias de rotina cumprem papel importante na identificação da lesão. A confirmação do diagnóstico é geralmente confirmada no ato cirúrgico, quando uma cavidade vazia é encontrada. Este relato de caso envolve uma situação clínica em que o cisto ósseo traumático foi diagnosticado a partir da documentação radiográfica ao final de um tratamento ortodôntico.

UNITERMOS: cisto ósseo traumático; diagnóstico; radiografia; tratamento ortodôntico.

INTRODUCTION

Maxillary cysts are not always easily diagnosed because they are generally asymptomatic. Traumatic bone cyst (TBC) may destroy the bone with no

clinical signals or symptoms. Routine radiographic exams play an important role in the diagnose of TBC which is often detected only by orthodontic documentation.

* Student – Graduate (Ph.D), Department of Orthodontics, Federal University of Rio de Janeiro. Assistant Professor, Department of Orthodontics, Federal Fluminense University, Rio de Janeiro, Brazil.

** Professor, Department of Oral Diagnosis and Pathology, Federal University of Rio de Janeiro, Rio de Janeiro, Brazil.

*** Professor, Department of General and Specialised Surgery, School of Medicine, Federal Fluminense University, Rio de Janeiro, Brazil.

TBC may be identified by a great variety of names in the literature, such as haemorrhagic bone cyst, simple bone cyst, solitary bone cyst, extravasation cyst, idiopathic bone cyst, primary bone cyst, and others. The international histological classification adopted by the World Health Organisation for odontogenic tumours uses the term “solitary bone cyst”,^{1,2} however the term “traumatic bone cyst” (TBC) is more widely used in the literature.³ The WHO classification describes TBC as a non-neoplastic osseous lesion because it shows no epithelial lining, which differentiates this lesion from the true cysts.²

As TBC is usually asymptomatic, it is often diagnosed incidentally during routine radiographic exams.^{4,6} The prevalence of TBC is of 1% amongst the maxillo-mandibular cystic lesions.⁷ Some studies state that TBC is more frequently seen in men^{1,7} although others have found no relationship to gender.^{6,8} TBC may occur in patients with ages varying from 2 to 75 years, but 56-70% of all cases are diagnosed during the second decade of life, and only 15% of the patients are more than 40 years of age.⁶ TBC is found almost exclusively in the mandible, being more frequently seen in the posterior region of the mandibular body,^{2,9} but it also can be located in the symphysis area.^{4,6}

Radiographically it is manifested as a well-defined, radiolucent, unilocular area, which occasionally presents a typical festooned pattern around the apexes of the adjacent teeth.^{3,4} In most cases TBC is within the medullar bone, and expansion of the cortical bone is rarely present. With its superior soft tissue contrast and multi-planar views, magnetic resonance imaging is the most useful modality for analysing the internal structure of the lesion and may have the ability to distinguish the TBCs from other odontogenic cysts or tumours. The magnetic resonance findings regarding TBCs show that they present non-epithelial lining and are generally filled with fluid.¹⁰ Surgical exploration is generally considered advisable to confirm the diagnosis and this in itself constitutes definitive treatment.^{4,11,12}

The objective of this study is to present and to discuss a case of traumatic bone cyst diagnosed after orthodontic treatment.

CASE REPORT

A 10-year-old girl with late mixed dentition presented normal oral structures on clinical and radiographic examination. Orthodontically, she had a Class II Division 1 malocclusion, parabolic

dental arches with lower arch length deficiency of 3.0 mm, upper midline coincident with median palatine raphe, lower midline deviated rightwards in 1.0 mm, overjet, and overbite of 4.0 mm.

The cephalometric tracing and analysis revealed that both the upper and lower incisors had good relationship with the basal bone, but there was a poor relationship between maxilla and mandible regarding the posterior position of the latter in relation to the cranial base, which had corroborated for the need of orthodontic treatment.

The specific goals of the orthodontic treatment included maintaining the aesthetically harmonic facial characteristics, correcting the Class II molar relationship, aligning and levelling the upper and lower arches, correcting the deviated midline and establishing ideal overbite and overjet.

The treatment was performed by means of a cervical pull headgear appliance used for 12 hours a day not only to achieve normal Class I molar relationship, but also to restrain the effect on maxillary growth. The molars were banded and the remaining teeth bonded to a 0.022 × 0.028-inch edgewise appliance.

At the end of the treatment all the previously defined orthodontic goals had been achieved. Peri-apical radiographic exam was performed following appliance removal and revealed the presence of a radiolucent, well-defined image located below the right lower canine apex (Figure 1b) as well as the absence of a sclerotic rim. There were no clinical signals or symptoms and no history of trauma as well. Panoramic radiograph confirmed extension and location of the lesion (Figure 2a).

Computerised tomography revealed a round, unilocular, circumscribed litic formation of 1 cm in diameter with thin, well-defined rim located on the right side of the anterior mandible, next to right lower incisor and canine roots. This lesion promoted a slight thinning of lingual and buccal cortices, but the remaining bone structure was found to be preserved (Figures 3a and 3b). The following diagnosing hypotheses were considered: traumatic bone cyst, aneurysmal bone cyst, and central giant cell lesion, in addition to other odontogenic cysts and tumours.

A new panoramic radiograph was requested 4 months later to evaluate the lesion previously seen on the films and it was found that the radiolucent area had expanded (Figure 2b). Exploratory biopsy or surgical removal of the lesion was indicated. An empty cavity was found during surgical procedure and a curettage was performed in order to obtain some material for histopathological analysis.

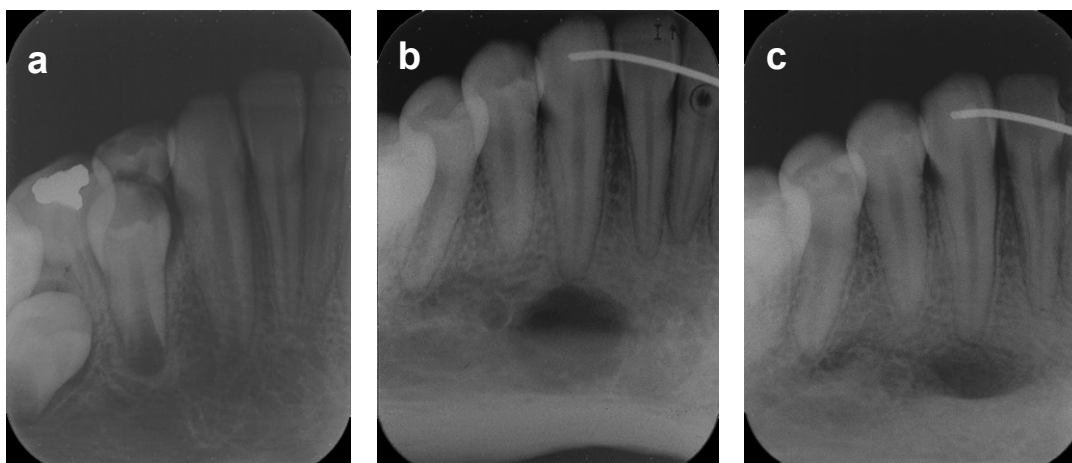


Figure 1 – A series of periapical radiographs: **a** - no pathology before orthodontic treatment; **b** - radiolucent image circumscribed below the right lower canine apex following orthodontic treatment; **c** - evidence of osseous repair occurring locally 8 months after the surgical intervention.

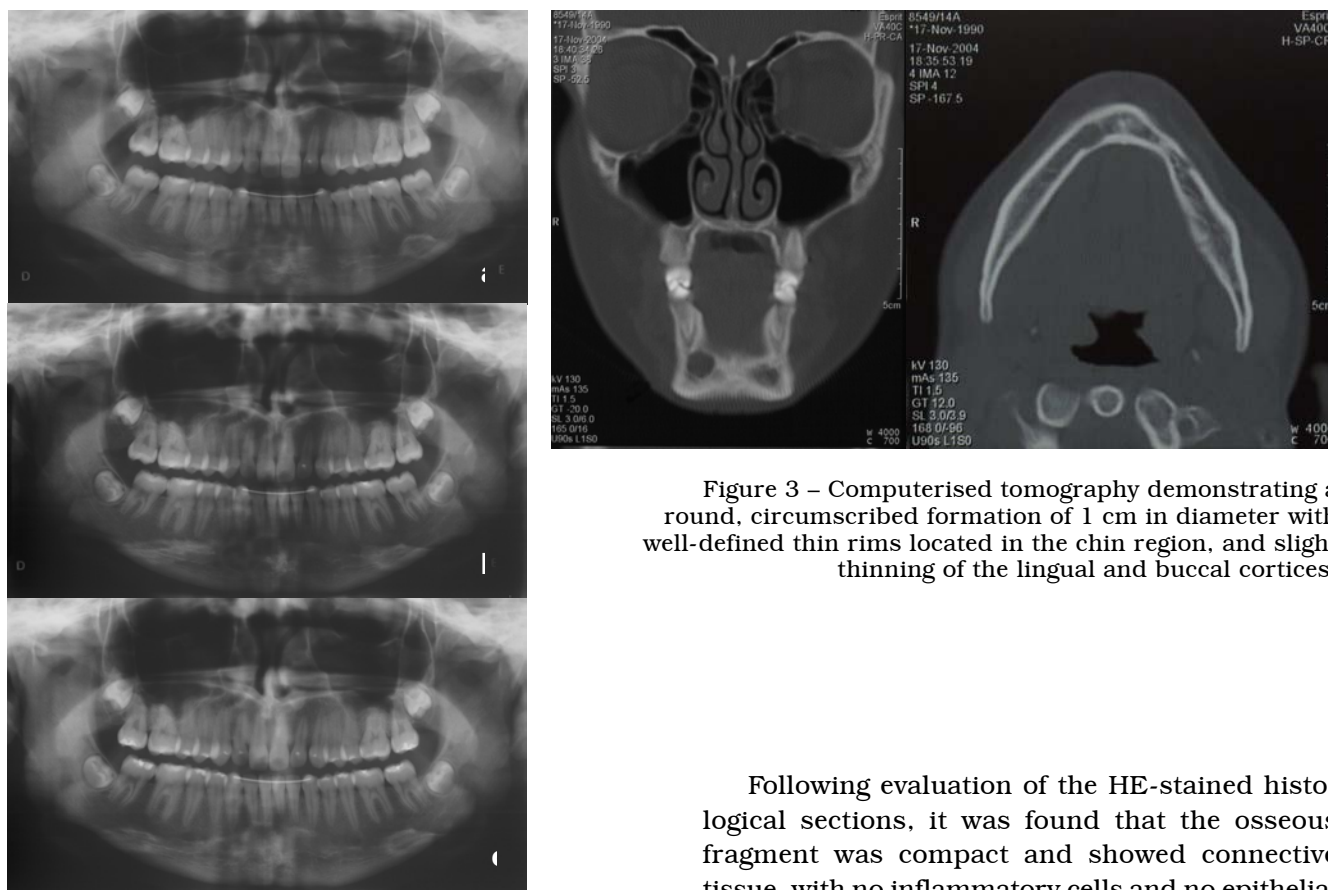


Figure 2 – A series of periapical radiographs: **a** - radiolucent image in the region of the right lower canine following orthodontic treatment; **b** - increased radiolucent image 4 months later; **c** - evidence of osseous repair occurring locally 8 months after the surgical intervention.

Figure 3 – Computerised tomography demonstrating a round, circumscribed formation of 1 cm in diameter with well-defined thin rims located in the chin region, and slight thinning of the lingual and buccal cortices.

Following evaluation of the HE-stained histological sections, it was found that the osseous fragment was compact and showed connective tissue, with no inflammatory cells and no epithelial tissue (Figures 4a and 4b). The TBC diagnosis was based on clinical, surgical, and histopathological characteristics.

New panoramic and periapical follow-up radiographs of the previously affected region taken eight months after the surgical intervention showed that the process of bone repair had occurred locally (Figures 1c and 2c).

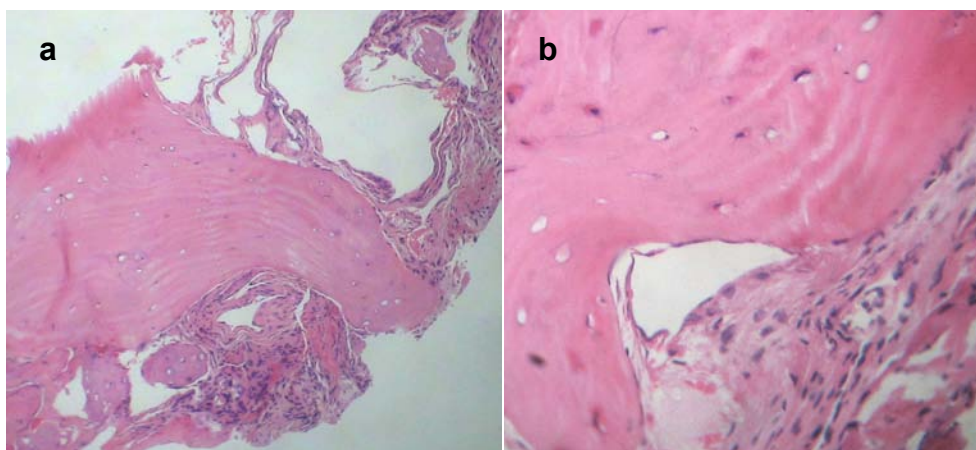


Figure 4 – HE-stained histological findings: **a** - Compact bone fragments and connective tissue lining the lesion wall (10× magnification); **b** - compact bone, presence of osteocytes and connective tissue and absence of inflammatory cells and epithelial tissue (40× magnification).

DISCUSSION

The clinical case reported is a TBC that has been diagnosed during final documentation at the end of the orthodontic treatment. Most of the clinical characteristics of the presented case is according to the literature. However, this TBC was located in the apical region of the right lower canine. TBC occurs more commonly in the mandible, predominantly in the posterior region,^{2,9} but there are reports on the predominance of such a lesion in the mandibular anterior region.^{4,6}

Although some bone cysts resolve spontaneously,¹³ surgical intervention is usually indicated not only for confirming the diagnosis, but also because the simple exploration of the cyst may be curative.⁴ Therefore, curettage of the cavity wall is generally indicated.¹² Osseous regeneration can be verified after some months, which was also observed in the described case (Figures 1c and 2c).

A great variety of names found in the literature across the world are likely related to the fact that both aetiology and pathology of the traumatic bone cysts are unknown. The trauma theory concerning the cyst formation is impaired by the difficulty in determining the trauma history, since there may be other possible relationships involving other stimuli.¹⁴ The most widely accepted explanation is the occurrence of trauma followed by intra-medullar haemorrhage with lack of haematoma organization, which would result in an empty cavity.^{5,6} Both history and nature of the trauma are rarely established. Other theories include cystic degeneration of fibro-osseous lesions, intra-

osseous vascular anomalies, alteration of bony metabolism and low level of infection.⁵

In 2003, Guerra evaluated 26 patients who had traumatic bone cyst and he found that 22 patients were in their 2nd decade of life, 30.77% had trauma history, 69.23% had some relation to orthodontic treatment, and 50% of all cases had been diagnosed during initial orthodontic documentation.¹⁴

The identification of traumatic bone cysts in some orthodontic patients is not surprising, since the age group in which this pathological change is more commonly seen, that is, 2nd decade of life, corresponds to the period in which most young patients submit to orthodontic therapy, as occurred in the above mentioned case. Furthermore, as radiographs are systematically used for orthodontic documentation, the diagnosis of such lesions among orthodontic patients is made easy.

CONCLUSION

Detection of traumatic bone cysts has often been related to radiographic examination regularly performed in orthodontics, since systematic documentation for planning and controlling the treatment is necessary. Therefore, orthodontics plays an important role in this context. The possible implication of the orthodontic treatment for TBC aetiology and pathogenesis has not been discussed enough in the literature. Further research should be carried on the relationship between orthodontic tooth movement and TBC appearance.

REFERENCES

1. Beasley JD, 3rd. Traumatic cyst of the jaws: report of 30 cases. *J Am Dent Assoc.* 1976;92:145-52.
2. Kramer IR, Pindborg JJ, Shear M. The WHO Histological Typing of Odontogenic Tumours. A commentary on the Second Edition. *Cancer.* 1992; 70:2988-94.
3. Copete MA, Kawamata A, Langlais RP. Solitary bone cyst of the jaws: radiographic review of 44 cases. *Oral Surg Oral Med Oral Pathol Oral Radiol Endod.* 1998;85:221-5.
4. Penarrocha-Diago M, Sanchis-Bielsa JM, Bonet-Marco J, Minguez-Sanz JM. Surgical treatment and follow-up of solitary bone cyst of the mandible: a report of seven cases. *Br J Oral Maxillofac Surg* 2001;39:221-223.
5. Baqain ZH, Jayakrishnan A, Farthing PM, Hardee P. Recurrence of a solitary bone cyst of the mandible: case report. *Br J Oral Maxillofac Surg* 2005;43:333-335.
6. Hansen LS, Sapone J, Sproat RC. Traumatic bone cysts of jaws. *Oral Surg Oral Med Oral Pathol.* 1974;37:899-910.
7. Saito Y, Hoshina Y, Nagamine T, Nakajima T, Suzuki M, Hayashi T. Simple bone cyst. A clinical and histopathologic study of fifteen cases. *Oral Surg Oral Med Oral Pathol.* 1992;74:487-91.
8. Jacobs MH. The traumatic bone cysts. *Oral Surg Oral Med Oral Pathol.* 1955;8:940-9.
9. Forssell K, Forssell H, Happonen RP, Neva M. Simple bone cyst. Review of the literature and analysis of 23 cases. *Int J Oral Maxillofac Surg.* 1988;17: 21-24.
10. Matsuzaki H, Asaumi J-i, Yanagi Y, Konouchi H, Honda Y, Hisatomi M et al. MR imaging in the assessment of a solitary bone cyst. *European Journal of Radiology Extra.* 2003;45:37-42.
11. DeTomasi D, Hann JR. Traumatic bone cyst: report of case. *J Am Dent Assoc.* 1985;111:56-7.
12. Kaugars GE, Cale AE. Traumatic bone cyst. *Oral Surg Oral Med Oral Pathol.* 1987;63:318-24.
13. Sapp JP, Stark ML. Self-healing traumatic bone cysts. *Oral Surg Oral Med Oral Pathol.* 1990;69: 597-602.
14. Guerra ENdS, Damante JH, Janson GRP. Relação entre o tratamento ortodôntico e o diagnóstico do cisto ósseo traumático. *R Dental Press Ortop Facial.* 2003;8:41-8.

Recebido para publicação em: 17/11/2006; aceito em: 29/03/2007.

Endereço para correspondência:
 ANDRÉA FONSECA JARDIM DA MOTTA
 Av. Engenheiro Martins Romeu, 41/803 – Boa Viagem
 CEP 24210-400, Niterói, RJ, Brasil
 E-mail: andreamotta@vm.uff.br